

Serum C-reactive protein is linked to cerebral microstructural integrity and cognitive function

H. Wersching, MD, T. Duning, MD, H. Lohmann, PhD, S. Mohammadi, PhD, C. Stehling, MD, M. Fobker, MD, M. Conty, J. Minnerup, MD, E.B. Ringelstein, MD, K. Berger, MD, M. Deppe, PhD and S. Knecht, MD

From the Department of Neurology (H.W., T.D., H.L., S.M., M.C., J.M., E.B.R., M.D., S.K.), Institute of Epidemiology and Social Medicine (H.W., K.B.), Institute of Clinical Radiology (C.S.), and Institute of Clinical Chemistry and Laboratory Medicine (M.F.), University of Münster, Münster, Germany.

Address correspondence and reprint requests to Dr. Heike Wersching, Institute of Epidemiology and Social Medicine, University of Münster, Domagkstraße 3, 48149 Münster, Germany
[werschin@uni-muenster.de](mailto:wersch@uni-muenster.de)

Objective: C-reactive protein is a marker of inflammation and vascular disease. It also seems to be associated with an increased risk of dementia. To better understand potential underlying mechanisms, we assessed microstructural brain integrity and cognitive performance relative to serum levels of high-sensitivity C-reactive protein (hs-CRP).

Methods: We cross-sectionally examined 447 community-dwelling and stroke-free individuals from the Systematic Evaluation and Alteration of Risk Factors for Cognitive Health (SEARCH) Health Study (mean age 63 years, 248 female). High-field MRI was performed in 321 of these subjects. Imaging measures included fluid-attenuated inversion recovery sequences for assessment of white matter hyperintensities, automated quantification of brain parenchyma volumes, and diffusion tensor imaging for calculation of global and regional white matter integrity, quantified by fractional anisotropy (FA). Psychometric analyses covered verbal memory, word fluency, and executive functions.

Results: Higher levels of hs-CRP were associated with worse performance in executive function after adjustment for age, gender, education, and cardiovascular risk factors in multiple regression analysis ($\beta = -0.095$, $p = 0.02$). Moreover, higher hs-CRP was related to reduced global fractional anisotropy ($\beta = -0.237$, $p < 0.001$), as well as regional FA scores of the frontal lobes ($\beta = -0.246$, $p < 0.001$), the corona radiata ($\beta = -0.222$, $p < 0.001$), and the corpus callosum ($\beta = -0.141$, $p = 0.016$), in particular the genu ($\beta = -0.174$, $p = 0.004$). We did not observe a significant association of hs-CRP with measures of white matter hyperintensities or brain atrophy.

Conclusion: These data suggest that low-grade inflammation as assessed by high-sensitivity C-reactive protein is associated with cerebral microstructural disintegration that predominantly affects frontal pathways and corresponding executive function.

Abbreviations: CRP = C-reactive protein; DTI = diffusion tensor imaging; FA = fractional anisotropy; FLAIR = fluid-attenuated inversion recovery; GMF = gray matter fraction; hs-CRP = high-sensitivity C-reactive protein; ROI = region of interest; SEARCH = Systematic Evaluation and Alteration of Risk Factors for Cognitive Health; TE = echo time; TI = inversion time; TR = repetition time; WM = white matter; WMF = white matter fraction; WMH = white matter hyperintensities.

Editorial, page 1014

Supplemental data at www.neurology.org

*These authors contributed equally.

Study funding: Supported by the Deutsche Forschungsgemeinschaft (Kn 285/6-1 and 6-3), Volkswagen Stiftung (Az.: I/80 708), Marie Curie Research and Training Network: Language and Brain (RTN:LAB) funded by the European Commission (MRTN-CT-2004-512141), BMBF-Competence Network Mednet Atrial Fibrillation, BMBF-Research Consortium: 01GW0520, and the Neuromedical Foundation Muenster.

Disclosure: Author disclosures are provided at the end of the article.

Received July 30, 2009. Accepted in final form November 12, 2009.

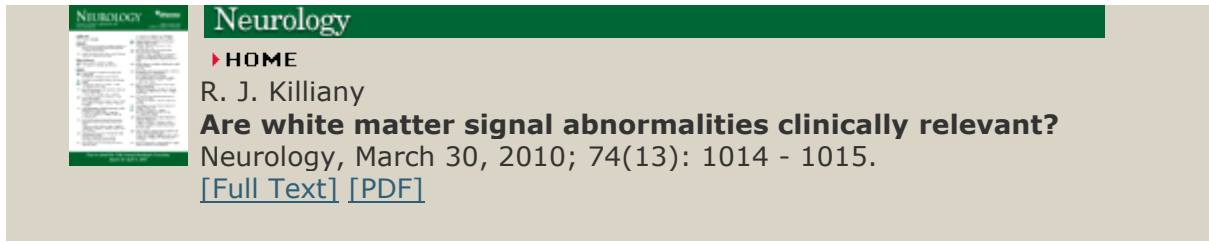
Related Article

Are white matter signal abnormalities clinically relevant?

Ronald J. Killiany

Neurology 2010 74: 1014-1015. [\[Full Text\]](#) [\[PDF\]](#)

This article has been cited by other articles:



Neurology

► **HOME**

R. J. Killiany

Are white matter signal abnormalities clinically relevant?

Neurology, March 30, 2010; 74(13): 1014 - 1015.

[\[Full Text\]](#) [\[PDF\]](#)